



## PATIENT

Happy Bernstein

## SPECIES

Feline

## BREED

DSH

## SEX

Female Spayed

## AGE

4 years

## WEIGHT

9.44lbs

## INTERPRETED BY

Maggie Machen Lamy,  
DVM, DACVIM  
(Cardiology)

## IMAGING PERFORMED BY

Potomac Mobile  
Veterinary Ultrasound

## HOSPITAL NAME

Clocktower Animal  
Hospital

## REFERRING VET

Dr. Jarrett

## INVOICE

25170

## DATE

7/6/22

## PRESENTING CLINICAL SIGNS

History: Grade 1-2/6 heart murmur. Mild ProBNP elevation: 111. Assess prior to anesthesia.

## ECHOCARDIOGRAM FINDINGS

2D, m-mode, color flow and doppler imaging is available. The left ventricular wall is irregular although overall normal in dimension. There is a mildly hyperechoic endocardium consistent with mild fibrosis. The endocardium also appears mildly remodeled. The papillary muscles are normal in size and hyperechoic. The left atrium is normal in size. The right atrium is normal in size. The right ventricle appears normal. The mitral valve is normal in structure and mobility. Trace TR. No other obvious valve regurgitation. Blood flow through both the LVOT and RVOT is normal in velocity. No pleural or pericardial effusion seen. No obvious cardiac tumors.

## CARDIAC CHART

FELINE CARDIAC PARAMETERS	BODY WEIGHT (kg)	HR (BPM)	IVSd (cm) (Moise, Pipers)	LVIDd (cm) (Moise, Pipers)	LWVd (cm) (Moise, Pipers)	FS (%)	EF (%)
NORMAL PARAMETER	-----	150-240	0.35-0.55	<2 (mean 1.5)	3.5-0.55	35-67	80-100
PATIENT	4.3	196	0.53	1.2	0.53	68	95
FELINE CARDIAC PARAMETERS	LA/AO (Boon)	LA/AO HEART BASE (Swe) (Abbott)	LA 2D short axis Base view (cm) (Abbott)		LVOT VEL (m/s)	RVOT VEL (m/s)	E max (m/s)
NORMAL	<1.5	<1.3	<1.2		<1.6	<1.3	<0.9
PATIENT	1.2	1.2	0.95		0.9	1.0	NM

*\*Note: All measurements based upon multi-modal images and methods. An average value is reported.*  
 Adapted from June Boon, Veterinary Echocardiography, 1998  
 Abbott J & MacLean H JVIM 2006;20: 111-119, Moise et al. Am J Vet Res 47:1476, 1986. Pipers et al. Am J Vet Res 40:882, 1979.

## INTERPRETATION OF THE FINDINGS & FURTHER RECOMMENDATIONS

Overtly normal cardiac structure and function. The LV wall thickness is normal, and there is no evidence of elevated left atrial pressure or underlying pathology at this time. There is more remodeling and fibrosis than suspected of a 4-year-old cat and follow up is advised. Finally, no cause for the murmur is identified, making it likely physiologic in origin. Given these findings, no medications are indicated.

No obvious structural cause for BNP elevation is seen here. A flaw of the BNP test is false positives, which may be the case; however, alternative causes for elevation should be considered, including decreased renal clearance, hypertension, etc. If no obvious cause is identified, reassessing this patient in 6-12 months is recommended to ensure early disease was not missed.

Anesthetic risk is considered mild. With remodeling and diastolic stiffening, there is an elevated risk for fluid overload in this patient and judicious IV fluid use is recommended. Heart rate stimulating drugs such as atropine, glycopyrrolate or ketamine should be avoided unless medically necessary. Risk for complication with steroid use typically follows LA dilation, which in this case is low. That being said, any cat can experience unexpected signs of intolerance and monitoring of RR/RE is advised particularly in the initiation phase.



**PATIENT**

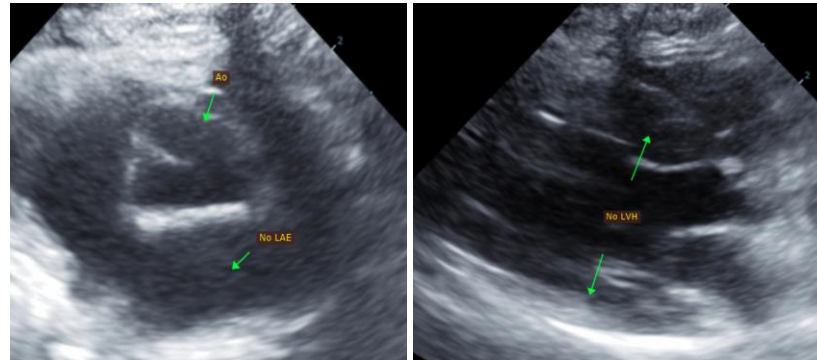
Happy Bernstein

Recommend recheck echocardiogram in 1 year to assess for any progressive issues.

**SPECIES**

Feline

**IMAGES**



**BREED**

DSH

**SEX**

Female Spayed

**AGE**

4 years

The information and recommendations provided are based on the images presented by the referring veterinarian. No evaluation can be communicated regarding pathology that was not visible in the image/video clips provided.

**WEIGHT**

9.44lbs

Thank you for this referral. This report was generated using transcription software, and minor dictation errors may be present. If the clinical or image interpretation does not parallel your findings or if I can be of any further assistance, please contact me.

**INTERPRETED BY**

Maggie Machen Lamy,  
DVM, DACVIM  
(Cardiology)

**Maggie Machen Lamy, DVM**  
Diplomate of the American College of Veterinary Internal Medicine (Cardiology)  
info@sonopath.com

**IMAGING PERFORMED BY**

Potomac Mobile  
Veterinary Ultrasound

**HOSPITAL NAME**

Clocktower Animal  
Hospital

**REFERRING VET**

Dr. Jarrett

**INVOICE**

25170

**DATE**

7/6/22